

peer reviewed **ARTICLE OF INTEREST**

## A case study of air in the vagina at screening CT colonography including incidental visualisation of a rectovaginal fistula

JH Bortz MB ChB (Cape Town), DMRD (London), FRCR (London), FFRRCS (Ireland)

Radiologist, California

### Abstract

This paper describes visualisation of air in the vagina at computer tomographic colonography (CTC). Images of normal air in the vagina, as well as demonstration of a rectovaginal fistula, seen at screening CTC are presented. A brief discussion is presented on the role of diagnostic imaging modalities to visualise the pelvic region in female patients. Pathological conditions may cause air in the vagina. It is therefore important to carefully check the vagina when interpreting imaging examinations.

**Keywords** vaginal flatus, queefing, yoga, prolonged labour

### Introduction

Screening computer tomographic colonography (CTC) allows visualisation of the colon as well as extracolonic structures. From time to time vaginal air may be seen on 2D images. It is not unusual to see a bubble of air within a normal vagina in up to 11% of patients.<sup>[1]</sup> However, large amounts of air usually indicate a pathological process: pelvic malignancy or inflammatory bowel disease, Crohn's disease, for example. It is important to carefully examine these images to exclude pathological causes. Anatomy of the vagina, as well as normal and pathological causes of vaginal air, are discussed. A range of normal images of vaginal air is presented as well as images of a rectovaginal fistula seen at screening CTC. To the best of the author's knowledge there are no previous publications of vaginal air seen at screening CTC.

### Anatomy of the vagina and causes of vaginal air

The vagina is an elastic fibromuscular like structure canal that connects the vulva to the cervix and uterus. It is located in the middle compartment of the pelvis, with the bladder and urethra lying anteriorly and the lower rectum and anal canal posteriorly. It lies at a 90 degree angle in relation to the uterus and is held in place by endopelvic fascia and ligaments. The distal third of the vagina is at the level of the urethra, the middle third at the level of the urinary bladder, the proximal third is at the level of the cervix and cervical canal. Its shape and length may vary widely because of the surrounding

structures; the length may vary from 8 to 12cm. The shorter anterior wall ends in the anterior fornix, and the longer wall in the posterior fornix.<sup>[2]</sup> The vaginal wall has three layers: (i) the mucosa which is squamous epithelium with no glands, (ii) the muscularis layer made up of collagen, elastic and smooth muscle, and (iii) the adventitia, which connects the vagina to the surrounding pelvic structures.<sup>[2-4]</sup> The vagina has the same density as the wall of the bladder, urethra, and rectum. At computer tomography (CT) examinations it is distinguished from them by the presence of a small fat layer. The presence of urine in the bladder, and air in the rectum, can help identify the vagina.<sup>[4]</sup> Insertion of a tampon will give good delineation of the vagina.

As there is a direct communication between the vagina and external air, it would be expected to find vaginal air during imaging examinations. The reason is that the vaginal walls are elastic and closely adjacent.<sup>[5]</sup> In the absence of symptoms, the presence of varying amounts of vaginal air would be a normal finding. In Figures 1a to c there is no evidence of air.

If air is present it may be a single bubble or two, and may be rounded, horizontal, vertical or curvilinear (Figures 2a to g). If a cluster of bubbles is identified it may indicate pathology such as an underlying infection or malignancy.

Depending on the amount of air in the vagina, expulsion of this air is known as vaginal flatus. It is different from rectal flatus because there is no odour, and is colloquially called 'queefing'. Common

causes of air in the vagina may result from sexual intercourse, insertion of a vaginal speculum during a gynaecological examination, or insertion of a tampon. Figures 3a and b show air and tampon in the vagina.

Yoga, with its range of poses, is probably the most common cause of varying amounts of vaginal air, and may cause considerable embarrassment to participants. A recent screening CTC examination of an asymptomatic female demonstrated a large amount of vaginal air as evident in Figures 4a to c. On close questioning her it was ascertained that she had been at a yoga class an hour before the CTC. She explained that it is not uncommon for air to enter and be expelled (queefing) from the vagina during yoga.

### Pelvic floor: its relevance in causes of air in vagina

The pelvic floor refers to the levator ani, the urinary and anal sphincter mechanisms, and the fascial supports of the pelvic viscera. This includes the rectum, vagina, bladder and urethra.<sup>[3,6]</sup> Pregnancy and previous childbirth, followed by pelvic floor weakness, are also causes of vaginal air.<sup>[7]</sup> Exercises to reduce pelvic floor muscle weakness from pregnancy or childbirth<sup>[2]</sup> may reduce passing of vaginal wind. The findings of a fairly recent study of 1000 patients, with a 'noisy' vagina, concluded that low age, low body mass index and vaginal delivery all affected the incidence of vaginal wind.<sup>[7]</sup> The prevalence of vaginal flatus in the study was 20%.

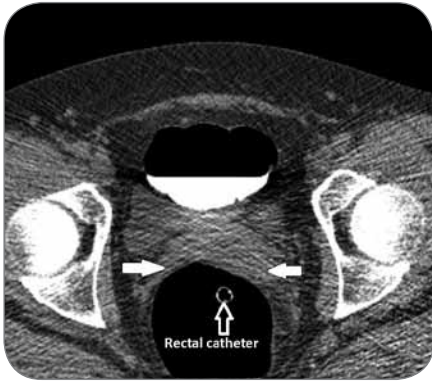


Figure 1a: 2D axial viewing showing normal vagina without air (white arrows) and rectal catheter.

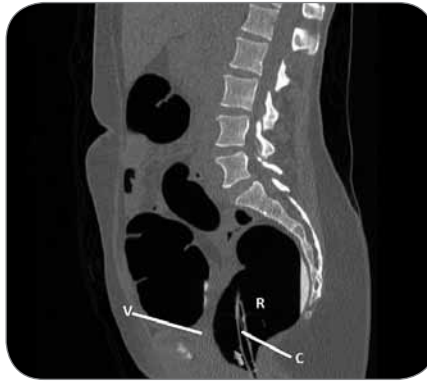

Figure 1b: Sagittal view showing no air in the vagina (V). Rectal catheter (C). Rectum (R).

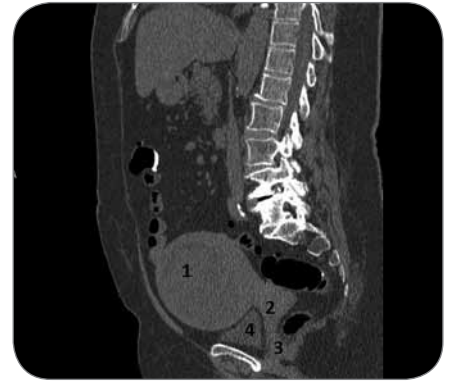


Figure 1c: Sagittal view showing enlarged uterus (1), cervix (2), vagina (3), and bladder (4).

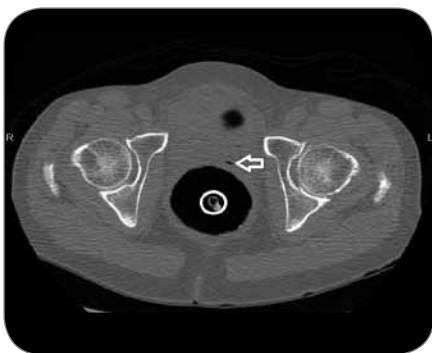


Figure 2a: 2D axial showing solitary air bubble in the vagina (open white arrow). Circle = rectal catheter.

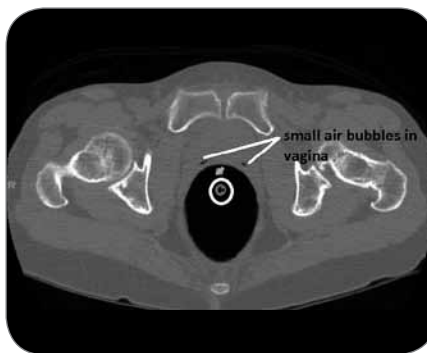


Figure 2b: 2D axial view showing two small air bubbles in the vagina. Circle = rectal catheter.

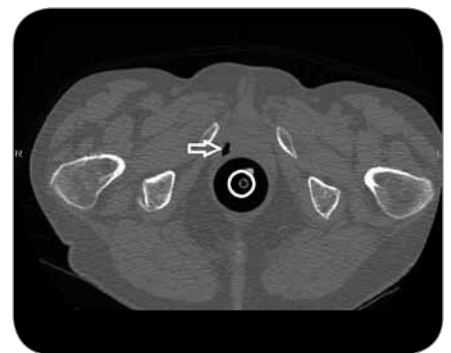


Figure 2c: 2D axial view showing curvilinear air in vagina (open white arrow). Circle = rectal catheter.

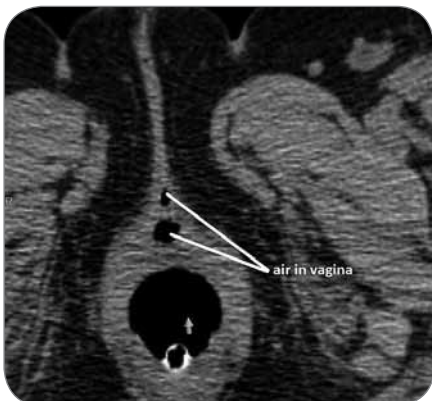


Figure 2d: 2D axial view showing air in the vagina.

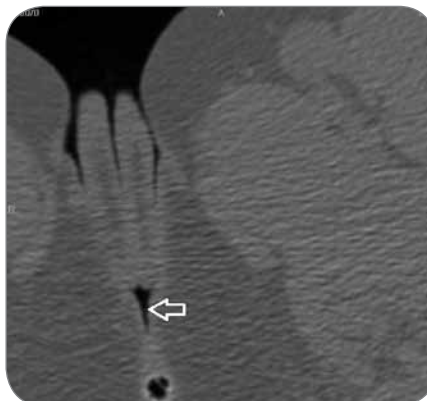


Figure 2e: 2D axial view showing air in the vagina (open white arrow).

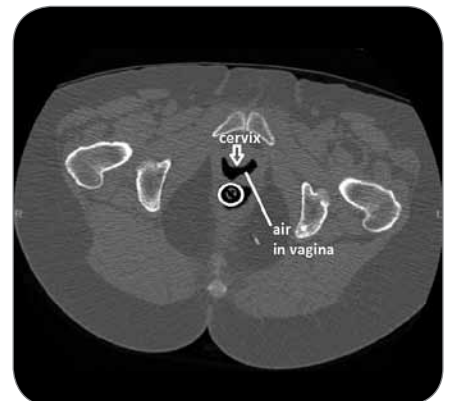

Figure 2f: 2D axial view showing cervix outlined by air in the vagina.

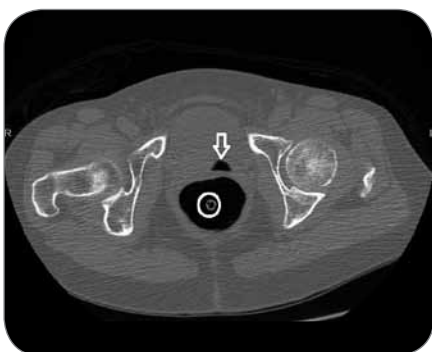


Figure 2g: 2D axial showing a triangular shape air bubble in the vagina (open white arrow). Circle = rectal catheter.

**Imaging of the pelvic region in female patients: ultrasound, magnetic resonance imaging, and CT**

Ultrasound (US), magnetic resonance imaging (MRI), and CT are used to visualise the pelvic region in female patients. Ultrasound is recommended as the first-line imaging modality in the American College of Radiology (ACR) appropriateness criteria for investigation of pelvic pathology for the following reasons.<sup>[4]</sup>

Advantages of US are:

- It is readily available
- It has high resolution
- It is cost-effective
- It does not involve ionising radiation

Its limitations are:

- It is operator dependent in terms of the expertise of the operator
- Patient obesity<sup>[4]</sup>

MRI, with its exceptional soft tissue resolution, is the best imaging modality to vis-

ualise the vagina. However, the American College of Radiology (ACR) only recommend MRI for cases in which ultrasound is inconclusive or non-diagnostic.<sup>[4]</sup> The use of standard sequences, together with a pelvic phased-array coil is usually sufficient for diagnosis, and may be supplemented by intravenous contrast and endovaginal gel.

Although CT is not usually the modality of choice in investigation of pelvic disease, it has a role in staging pelvic malignancy and its follow-up, especially with the use of multiplanar reformatted images.<sup>[4]</sup> The CT appearance of a normal vagina is that of an elongated semilunar soft tissue organ, which has poor soft tissue characteristics compared with US and MRI. CTC has not been included in the literature for visualisation of normal and pathological causes of air in the vagina.

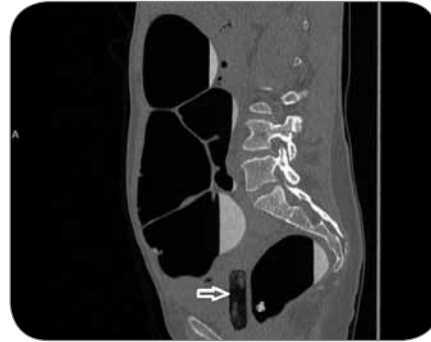
### Most common pathological causes of air in the vagina

The most common pathological conditions that cause vaginal air include

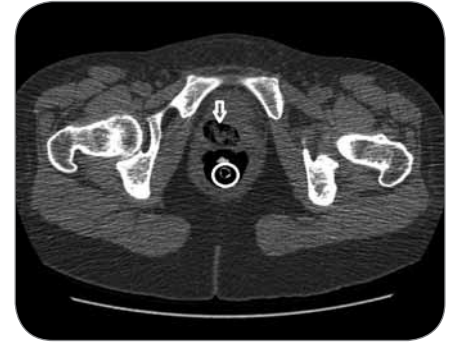- Inflammatory bowel disease, especially Crohn's disease. Note that CTC is not performed on patients with inflammatory bowel disease<sup>[8,9]</sup>
- Pelvic malignancies arising from the cervix or uterus; vaginal secondaries from breast cancer or melanoma
- Radiotherapy to the pelvis
- Pelvic floor dysfunction or prolapse following childbirth, enterocele, rectocele, or vaginal prolapse<sup>[10]</sup>
- Recto or colo-vaginal fistula from multiple causes.

### The main cause of rectovaginal fistula and imaging modality options

A fistula is an abnormal tract that connects



**Figure 3a:** Sagittal view showing tampon with air in the vagina (open white arrow).



**Figure 3b:** 2D supine axial view showing tampon with air in the vagina (open white arrow). Catheter = circle.

two epithelial surfaces.<sup>[11,12]</sup> The main causes of rectovaginal fistula (RVF) in the developing world is from pressure necrosis from obstructed and prolonged labour. Necrosis on the rectovaginal septum or an obstetrical injury with third or fourth degree perineal tear or episiotomy can lead to RVF.<sup>[13]</sup> Other causes may include neglected foreign bodies, coital injury, and local treatment by an unqualified practitioner.<sup>[14]</sup> In the developed world the main causes are surgery, malignancy, radiotherapy or a combination of them.<sup>[14]</sup> Physical examination is important to try to locate the fistula and examine the surrounding tissue. Imaging studies that may be employed are varied and carried out to determine the presence of a fistula and the extent of the underlying disease.

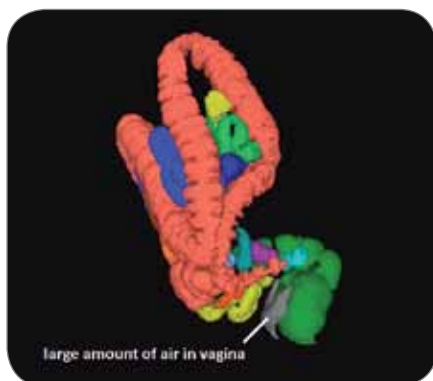Ultrasound, in the form of endorectal and transvaginal techniques, as well as perineal ultrasound with 3D, may identify a low fistulous tract. A rectal enema using methylene blue dye, together with a tampon inserted into the vagina, may be useful. After retaining the enema for 20 minutes, the tampon is removed and examined for blue dye staining. It is highly unlikely that there is a RVF if staining is

not detected. If the fistula is thought to be more proximal, a CT scan with rectal contrast may be performed. MRI has been described as having increasing effectiveness for imaging fistula.<sup>[11]</sup> It is a costly examination and requires expertise in interpreting the images.<sup>[4]</sup>

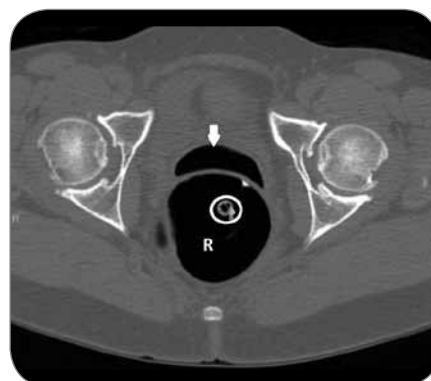
A relatively new technique in the form of CT colonography may also be attempted to visualise the RVF. In this imaging examination the bowel is adequately cleansed, and distended with CO<sub>2</sub>. CT scans at 1mm thick with a 1.25mm interval can be performed. The fistulous tract may be demonstrated as presented in the discussion below.

### Rectovaginal fistula (RVF) seen at CTC study

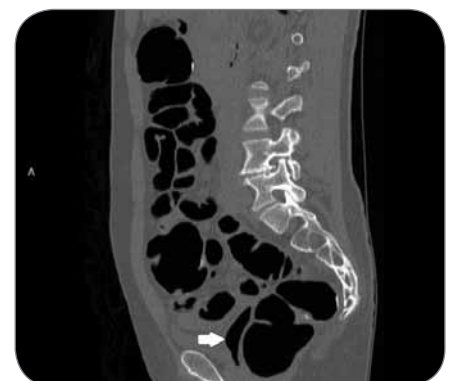Figures 5a to e are of a RVF that was demonstrated at a screening CTC examination on a 52 year old female. The findings were of a normal colon except for the fistulous communication between her rectum and vagina. On close questioning she provided a history of a prolonged and difficult labour 12 years earlier. An episiotomy and forceps' delivery were performed. After several months she noted a



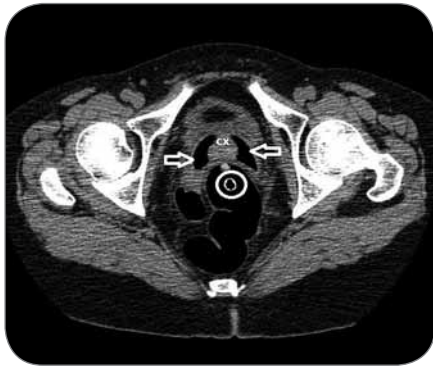**Figure 4a:** Colon-map showing air in the vagina (grey).



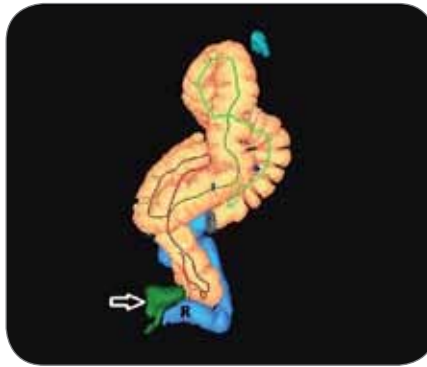
**Figure 4b:** 2D axial view showing a large amount of air in the vagina (white arrow). R = rectum; circle = catheter. This air was caused by yoga exercises.



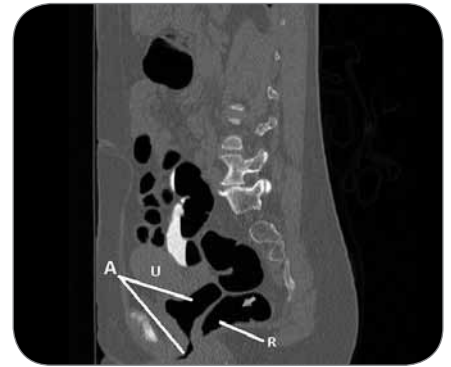
**Figure 4c:** Sagittal view showing a large amount of air in the vagina (white arrow) post yoga exercises.



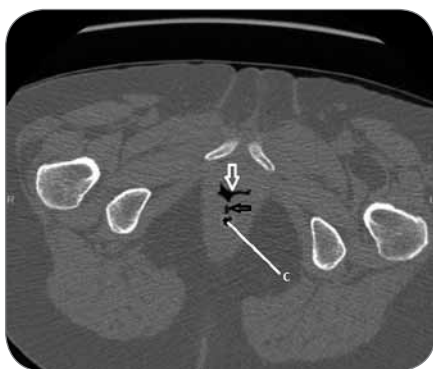**Figure 5a:** 2D axial view showing air in the vagina (open white arrows) with no fistulous tract. Cervix (cx). Rectal catheter (white circle).



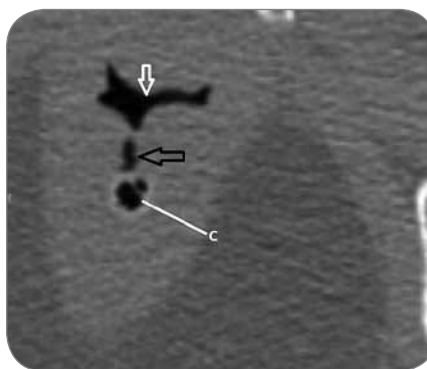
**Figure 5b:** Lateral colon-map showing air in the vagina (open white arrow and green). R = rectum.



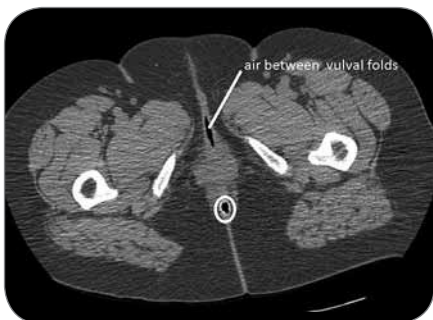
**Figure 5c:** Sagittal view showing air in the vagina (A). Rectovaginal fistula = bottom white line. Rectum (R). Uterus (U).



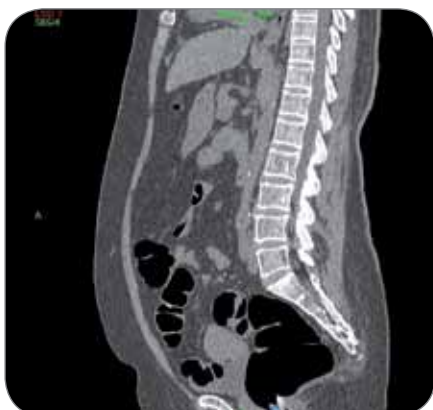**Figure 5d:** 2D prone axial demonstrates a fistulous tract (open black arrow) between the rectum (C = rectal catheter) and the vagina (open white arrow).



**Figure 5e:** 2D close-up view showing the rectovaginal fistula. Open black arrow = fistulous tract; open white arrow = air in the vagina; C = rectal catheter.



**Figure 6a:** Axial supine view showing air between vulval folds. White circle = rectal catheter.



**Figure 6b.** It is important to check sagittal view for air in vagina. This view of the patient in figure 6a shows no air in the vagina.

foul smelling vaginal discharge with some faecal particles being observed. A gynaecological examination failed to demonstrate a fistulous communication hence no further interventions were attempted. The CTC was able to demonstrate the fistulous tract to good effect. To the best of the author's knowledge the use of CTC to demonstrate a RVF has not been described in the literature.

## Conclusion

It is important to not mistake air between vulval folds as being air in the vagina (Figures 6a and b). This paper underscores the importance of carefully checking for air in the vagina when interpreting CTC images to rule out a pathology, such as rectovaginal fistula. Most of the air seen in the vagina is a normal finding and requires no further investigations. If the history is suspicious for a pathology further imaging investigations, namely ultrasound, MRI and CT examinations should be used.<sup>[4]</sup>

## Competing interests

The author has no financial or personal relationships which may have inappropriately influenced him in writing this article.

## References

1. Nokes SR, Martinez CR, Arrington JA, Dautto R. Significance of vaginal air on computed tomography. *J Comput Assist Tomogr.* 1986; 10:997-999.
2. Barber MD. Contemporary views on female pelvic anatomy. *Cleveland Clinic J of Medicine.* 2005; 72(4):S3-S11.
3. Wei JT, De Lancey JOI. Functional anatomy of the pelvic floor and lower urinary tract. *Clinical Obstetrics and Gynecology.* 2004; 47 (1):3-17.
4. Walker DK, Saliban RA, Saliban AD et al. Overlooked diseases of the vagina: a directed anatomic-pathologic approach for imaging assessment. *RadioGraphics.* 2011; 31:1583-1598.
5. Hadar H, Kornreich L, Heifets M, Herskovits P, Horev G. Air in vagina. Indicator of intrapelvic pathology on CT. *Acta Radiologica.* 1999;32:170-173.
6. Maglinte Dean D, Bartram Clive I, Hale Douglas A. Functional imaging of the Pelvic Floor. *Radiology.* 2011; 258 (1):23-39.
7. Veisi F, Rezavand N, Zangeneh M, Malekkhosravi S, Rezaei M. Vaginal flatus and the associated risk factors in Iranian women: a main research article. *ISRN Obstetrics and Gynecology.* 2012. 802648. [cited 2017 January 30]. Available from: <http://doi.org/10.5402/2012/802648>.
8. Bortz JH. CT colonography: an approach for a successful examination. *S Afr J Rad.* 2014;18(1); [http:// dx.doi.org/10.4102/sajr.v18i1.607](http://dx.doi.org/10.4102/sajr.v18i1.607) [www.sajr.org.za].
9. Bortz JH. CTC technique and methods of interpreting images. In Bortz JH, Ramlal A, Munro L (eds). *CT colonography for radiographers. A guide to performance and image interpretation.* Basel: Springer. 2016: p105. Doi 10.1007/978-3-319-29379-0.
10. Krissi H, Medina C, Stanton SL. Vaginal wind—a new pelvic symptom. *International Urogynecology Journal and Pelvic Floor Dysfunction.* 2003;14(6):399-402.
11. Halligan S, Stoker J. State of the art: imaging of fistula in ano. *Radiology.* 2006; 239(1):18-33.
12. Champagne BJ, McGee MF. Retrovaginal fistula. *Surg Clin N Am.* 2010; 90:69-82.
13. deBeche-Adams TH, Bohl JL. Rectovaginal fistulas. *Clin Colon Rectal Surg.* 2010; 23:99-103.
14. Kelly J. Vesico-vaginal and recto-vaginal fistulae. *J of the Royal Soc of Med.* 1992; 85:257.